

Effect of Low Intensity Pulsed Ultrasound on Healing of an Ulna Defect Filled with a Bone Graft Substitute

William R. Walsh,¹ Andrew J. Langdown,¹ Jason W. Auld,¹ Paul Stephens,¹ Yan Yu,¹ Frank Vizesi,¹ Warwick J. M. Bruce,² Neill Pounder³

¹ Surgical and Orthopaedic Research Laboratories, University of New South Wales, Division of Surgery, Prince of Wales Hospital, Randwick, New South Wales, Australia

² Orthopaedic Department, Concord Hospital, Concord, New South Wales, Australia

³ Smith & Nephew Orthopaedics, Memphis, Tennessee

Received 22 May 2006; revised 16 July 2007; accepted 5 September 2007

Published online 12 December 2007 in Wiley InterScience (www.interscience.wiley.com). DOI: 10.1002/jbm.b.30989

Abstract: A 1.5 cm unilateral rabbit ulna defect model was performed in 18 adult NZ white rabbits. The defects were filled with a β -tricalcium phosphate bone graft substitute (JAX TCP). The surgical site in half the animals was treated daily with 20 min of low intensity pulsed ultrasound (LIPUS). Animals were sacrificed at 4 weeks ($n = 3$ per group) or 12 weeks ($n = 6$ per group) following surgery for radiographic and histologic endpoints. Radiography revealed some resorption of the JAX TCP by 12 weeks in the control and LIPUS treated groups. LIPUS treatment did not accelerate this resorption. Some new bone formation was noted in the control groups at the defect margins while little bone formed in the center of the defect at 4 and 12 weeks. In contrast, radiographs revealed more new bone at 4 and 12 weeks in the LIPUS treated animals throughout the section. Bone mineral density (DEXA) revealed a statistically significant difference at 4 weeks with LIPUS while no differences were found at 12 weeks. Histology of the LIPUS treated sections demonstrated new woven bone formation on and between the JAX TCP bone graft substitute particles across the defect. VEGF expression was increased with LIPUS treatment at 4 weeks and remained elevated at 12 weeks compared with controls. CBFA-1 expression levels were elevated with LIPUS treatment at both time points. LIPUS treatment increased bone formation in ulna defect healing with a β -tricalcium phosphate bone graft substitute. © 2007 Wiley Periodicals, Inc. *J Biomed Mater Res Part B: Appl Biomater* 86B: 74–81, 2008

Keywords: bone; histology; orthopaedic; bone graft

INTRODUCTION

Healing of bone defects continues to be a challenge in orthopaedic surgery. Osteoconductive bone graft substitutes provide an “off the shelf” option to treat bone defects alone or in combination with local autograft. While many of these materials have demonstrated that they are capable of supporting new bone formation *in vivo*, this is often limited to areas where the substitute is in close proximity to a bony bed supporting their osteoconductive nature.

Low intensity pulsed ultrasound (LIPUS) has been shown to augment bone healing in a variety of animal and clinical settings.^{1–7} LIPUS has also been shown to improve cartilage healing⁸ as well as endochondral ossification.⁹ In the case of bone defects and ultrasound treatment, the

results of animal studies remains controversial.^{7,10,11} Duarte reported a positive effect following LIPUS treatment in noncritical size (1.5 mm) cortical defects in rabbit femurs.¹¹ Similarly, Yang and Park reported a positive effect of LIPUS in small and large ulna defect in dogs⁷ although these defects were not a critical size. Schortinghuis et al. reported no effect of LIPUS treatment in a critical size mandible defect in rats.¹⁰ *In vitro* cell culture studies support the use of LIPUS in cartilage matrix production¹² as well as VEGF expression¹³ and nitric oxide and prostaglandin E2 production from local tissues¹⁴ and osteogenic activity of human periosteal cells.¹⁵

Healing of a critical size defect requires some type of bone graft material to act as a scaffold for the repair along with some cellular or inductive molecules to work in concert for healing to occur. The potential synergistic effect of low intensity pulsed ultrasound with a bone graft substitute to improve bone defect healing remains unclear. Bone graft substitutes provide a means to fill large defects in surgery

Correspondence to: W. R. Walsh (e-mail: w.walsh@unsw.edu.au)

© 2007 Wiley Periodicals, Inc.

but are often limited by their osteoconductive nature. LIPUS offers the potential to improve healing by increasing bone formation through a noninvasive treatment regime. We hypothesized that the addition of LIPUS treatment to a critical size defect filled with an appropriate bone graft substitute would aid in healing. A 1.5 cm ulnar defect in NZ White rabbits was used to compare healing with a β -tricalcium phosphate bone graft alone (JAX TCP; Smith & Nephew, Memphis, TN) and in conjunction with low intensity pulsed ultrasound (LIPUS) treatment daily at 4 and 12 weeks following surgery. Endpoints in this study included Faxitron radiographics, dual energy X-ray absorptiometry (DEXA), routine histology, and protein expression using immunohistochemistry.

MATERIALS AND METHODS

Ethical approval for the study was obtained from the University of New South Wales. The study design (Table I) encompassed a control group and a treatment group where low intensity pulsed ultrasound (LIPUS) was performed daily for 4 or 12 weeks. All surgery was performed by experienced orthopedic surgeons. A 1.5 cm defect was made in the right ulna of 18 adult NZ White Rabbits.^{16,17} The surgical site was referenced from the elbow to allow standard placement of the defect. A pneumatic powered oscillating saw was used to section the bone at both ends. The 1.5 cm bone fragment and periosteum was removed using a pair of forceps. The defects were filled with 12 β -tricalcium phosphate bone graft substitute particles (JAX TCP; Smith & Nephew, Memphis TN). JAX TCP is a commercially pure beta tricalcium phosphate that comes in particles 4 mm in length which have six arms emanating from central part of the particle. In half of the rabbits, the ulna defect site was treated with low intensity pulsed ultrasound (LIPUS) (Exogen; Smith & Nephew, Memphis TN) for 20 min per day ($n = 9$). The 1.5 MHz ultrasound signal provided 30 mW/cm² SATA with a pulse width of 200 μ s and a pulse frequency of 1 kHz. Animals designated for LIPUS were treated over the surgery site by placing a small amount of ultrasound gel over the surgical site as well as on the transducer.

Control and LIPUS treated animals were sacrificed at 4 weeks ($n = 3$ per group) and 12 weeks ($n = 6$ per group) after surgery. The harvested forelimbs were radiographed using an HP Faxitron (Wheeling, IL) and high-resolution mammography film (settings 24 kV for 45 s). These radiographs were evaluated for evidence of implant resorption and new bone formation by two blinded observers. A time zero radiograph of the JAX TCP material in a rabbit

TABLE I. Study Design

Group	4 Weeks (n)	12 Weeks (n)
Control	3	6
LIPUS	3	6

TABLE II. Radiographic Scoring

Site	Description	Grade
1	New bone formation at the proximal margin	0–3
2	New bone formation at the distal margin	0–3
3	New bone formation in the middle of the defect	0–3
4	New bone formation at the interface with the radius	0–3

Score 0 = no new bone formation; Score 1 = less than 25% of the defect site demonstrating new bone formation; Score 2 = less than 50% of the site demonstrating new bone formation; Score 3 = less than 75% of the site demonstrating new bone formation.

cadaver ulna defect was for radiographic comparison of resorption. A qualitative grading scale of 0 to 3 (Table II) was used to assess new bone formation within the defect itself at four sites; the proximal and distal ends, the middle of the defect, and the interface with the radius. The maximum radiographic score for a defect was set at 12. The radiographic scores were analyzed with a non-parametric (Mann–Whitney test) using SPSS for Windows (SPSS, Chicago, IL).

The samples were fixed in phosphate buffered formalin. Bone mineral density (BMD) was calculated for a defined region of interest (ROI) within the defect site using a Norland pDEXA Sabre scanner (Norland Medical Systems, New York, NY). DEXA scanning was performed on the operated (right side) in the lateral plane to allow visualization of the defect on the DEXA scan. The ROI excluded the adjacent radius and the bony margins of the defect in the scan. DEXA data was analyzed with a two-way analysis of variance using SPSS for Windows (SPSS, Chicago, IL).

The samples were decalcified in formic acid-formalin, embedded in paraffin and sectioned for routine histology using hemotoxylin and eosin (H&E) and Trichrome stains. The sample was split into two and sectioned along the long axis of the ulna and radius. Five-micron thick sections were cut using a Lecia microtome. Sections were placed on saline-coated slides for protein expression using immunohistochemistry (IHC). IHC was performed for VEGF and CBFA-1 expression using standard techniques.^{18,19} The primary antibodies specific to VEGF (monoclonal from mouse) and CBFA-1 (polyclonal from goat) were purchased from Santa Cruz (CA) using final concentrations were 1 and 5 μ g/mL, respectively. To rule out nonspecific binding, nonimmunized mouse and goat IgGs (Santa Cruz, CA) were tested at the same concentration as the primary antibodies simultaneously. The secondary antibodies and the visualization systems were purchased from DAKO (Glostrup, Denmark). The horseradish peroxidase and a liquid diaminobenzidine substrate-chromogen system were used to produce a brown end product at the site of the target proteins. The immuno-stained sections were counterstained with Harris haematoxylin and mounted with EUKITT medium and cover slips. Three blinded observers qualitatively assessed histology and immunohistochemistry for new bone formation, tissue reaction, and protein expression.

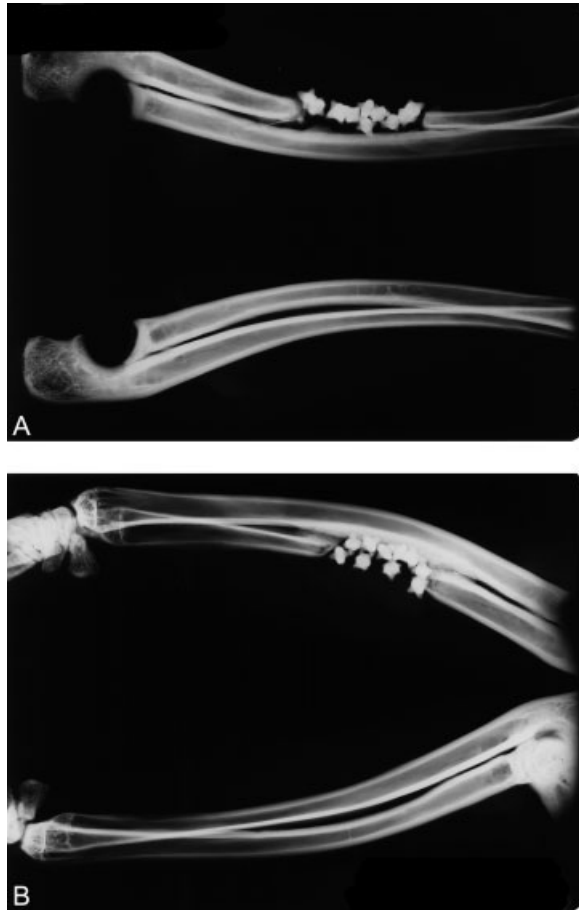


Figure 1. Representative faxitrons of control (A) and LIPUS (B) rabbit ulnas at 4 weeks. Unoperated limb shown for comparison.

RESULTS

No adverse events were encountered during surgery, post-operatively or during LIPUS treatment. Faxitron radiographs revealed some softening of the edges of the JAX TCP at 4 and 12 weeks in both control and LIPUS treated animals although no major loss of material was observed (Figures 1 and 2). LIPUS did not appear to alter the resorption rate of the JAX TCP based on the radiographs. New bone formation at the defect margins was consistently found where the JAX TCP particles were in direct contact with the adjacent bone. In contrast, defects filled with JAX TCP and treated with LIPUS demonstrated new bone formation compared with controls at 4 and 12 weeks at the host bone margins and within the defect itself between the JAX TCP particles. A statistical difference between the control and LIPUS treated animals was found at 12 weeks ($p < 0.05$) (Figure 3). The radiographic scores increased in the both groups between 4 and 12 weeks although no statistical differences were found (Figure 3).

The X-rays demonstrate the increased bone formation using LIPUS at 12 weeks. New bone formation was noted particularly when the TCP material was in direct contact with bone supporting the osteoconductive nature of this

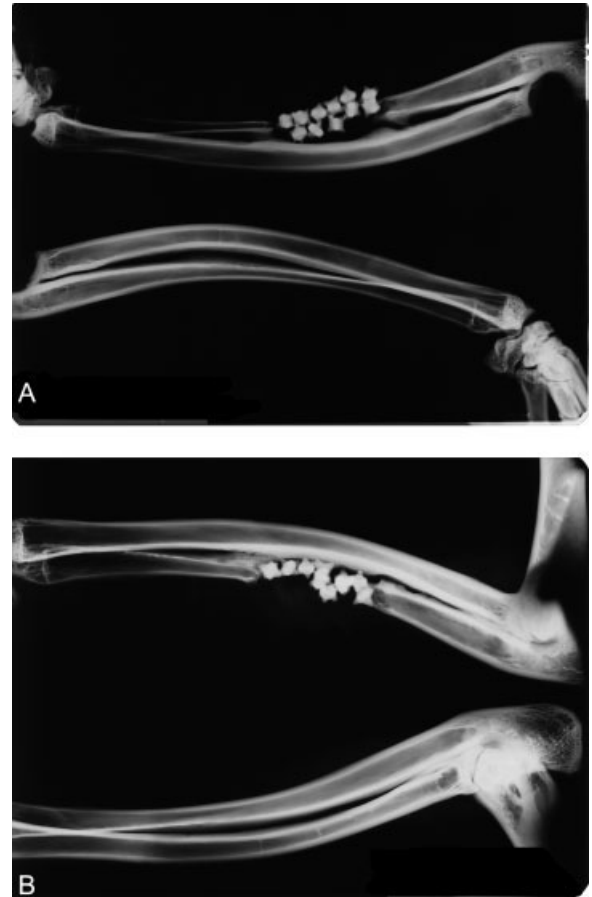

Figure 2. Representative faxitrons of control (A) and LIPUS (B) rabbit ulnas at 12 weeks. Unoperated limb shown for comparison.

material. LIPUS treatment increased the amount of new bone formation compared with the control (untreated) defects filled with JAX TCP alone. DEXA values increased in the control group between 4 and 12 weeks ($p < 0.05$). A significant increase in bone mineral density was noted with ultrasound treatment at 4 weeks ($p < 0.05$) (Figure 4) while no difference was observed at 12 weeks based on DEXA.

New woven bone was found in the LIPUS treated animals at 4 and 12 weeks compared with controls 12 weeks

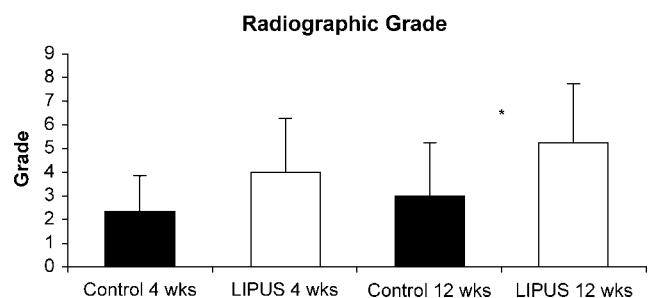


Figure 3. Radiographic analysis. A statistical difference was noted at 12 weeks between the control and ultrasound treated animals (* $p < 0.05$).

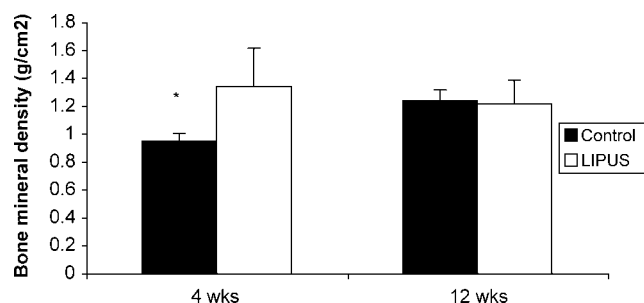


Figure 4. Bone mineral density. A statistical difference in DEXA density was observed at 4 weeks ($p < 0.05$) between the control and ultrasound treated ulna defects. No differences were found at 12 weeks.

[Figure 5(a–d)]. Soft tissue was noted between the TCP particles in the control group at 4 weeks [Figure 5(a,b)] while the addition of LIPUS treatment resulted in new woven bone between the TCP particles penetrating into the defect [Figure 5(c,d)]. New bone was noted in the control group only when the JAX TCP was in direct contact with a bony bed at 4 weeks. Histology of the TCP control at 12 weeks again demonstrated primarily fibrous and fatty tissue within the defect [Figures 6(a,b)] with some new bone formation when the JAX TCP was in contact with host bone. In contrast, histology of the JAX TCP with LIPUS at 12 weeks [Figures 6(c,d)] presented abundant bone between the JAX TCP particles with noted remodeling [Figure 6(d)]. Bone formation between the JAX TCP particles in the middle of the defect as well as the host bone was noted throughout the sections with LIPUS treatment at 12 weeks.

Immunohistochemistry

Immunohistochemistry for protein expression of VEGF-1 and CBFA1 was performed. VEGF-1 expression at 4 weeks was mainly observed in the osteoblast-like cells in the host bone adjacent to the JAX TCP particles. VEGF expression was elevated in the LIPUS treated animals compared with controls. The VEGF expression remained elevated at 12 weeks in the LIPUS treated group compared with controls (Figure 7). The elevated VEGF expression was associated with increased vascularity in the LIPUS treated animals.

CBFA1 expression was found at actively forming bone fronts at 4 and 12 weeks and the staining intensity and distribution were greater in the LIPUS treated animals compared with controls which is a reflection of more bone formation in the treatment groups. CBFA1 expression was most noted in active osteoblasts and mesenchymal cells adjacent to new bone formation (Figure 8).

DISCUSSION

Healing of large bone defects remains a clinical challenge. While osteoconductive bone graft substitutes provide a surgical means of filling large defects, they are often limited

by their lack of any inductive molecules to stimulate healing.^{20–25} New bone formation is often limited to areas where the bone graft substitute is in contact with native bone considering they are osteoconductive and not osteoinductive. This study examined if LIPUS, which is known to influence bone healing *in vivo*^{1–7} could improve or influence bone formation in a critical size ulna defect filled with a β -tricalcium phosphate bone graft (β TCP).

Radiographs, DEXA, and histology demonstrated a significant improvement in bone formation when LIPUS was applied to the defect sites filled with the β TCP particles compared with no LIPUS treatment at 4 weeks. Histology at 12 week histology revealed more bone which was remodeling in the LIPUS treated group compared with the control, no treatment group. VEGF and CBFA-1 expression was increased with LIPUS treatment, reflecting the increased healing response and degree of new bone generation. The mode of action of LIPUS is uncertain, but would appear to involve stimulation of osteoblast differentiation and of calcified matrix production¹⁴ along with increased expression levels of CBFA-1 as found in the current study. Studies on human periosteal cells have shown that LIPUS produces a dose-dependent increase in osteocalcin secretion, alkaline phosphatase activity, VEGF secretion, and calcium nodule formation, without an increase in cell number, suggesting that LIPUS stimulates differentiation toward osteogenic lineage.¹⁵

A β -tricalcium phosphate bone graft substitute (JAX TCP; Smith & Nephew, Memphis, TN) was chosen in the current study considering it is an osteoconductive scaffold. A number of studies have examined the *in vivo* response in bony sites for a variety of calcium phosphate based bone grafts^{20,21,24,26–36} in a variety of experimental sites demonstrating TCPs osteoconductive nature. *In vivo* resorption rates of β -TCP bone grafts have also been reported to be slower than that of hydroxyapatite³¹ but more rapid than α -TCP.³⁶ The ulna defect model is challenging with respect to bone healing as well as implant resorption considering the lack of local bone encompassing the defect site. Resorption of the β -TCP in the ulna defect model had not progressed very far at 12 weeks. Implant resorption was minimal at 4 weeks and agreed with the work of Wiltfang et al. for a different β -TCP bone graft (Cerasorb).³⁶ These authors reported 40% of Cerasorb remained in the defect at 16 weeks. Based on their data ~75% of the Cerasorb would have remained at a 12 week time point. Differences in anatomical sites, local blood supply, and the amount of surrounding bone between the ulna defect model compared with the cancellous defect in the proximal tibia³⁶ may account for the differences in resorption. The β -TCP in the current study did provide a scaffold for new bone ingrowth and ongrowth in the ulna defect model. Clarke et al.³⁷ recently reported ulnar defect using a JAX β -TCP bone graft substitute combined with autologous osteogenic cells and growth factors. Their observations suggest including osteogenic cells alone was insufficient to enhance bone

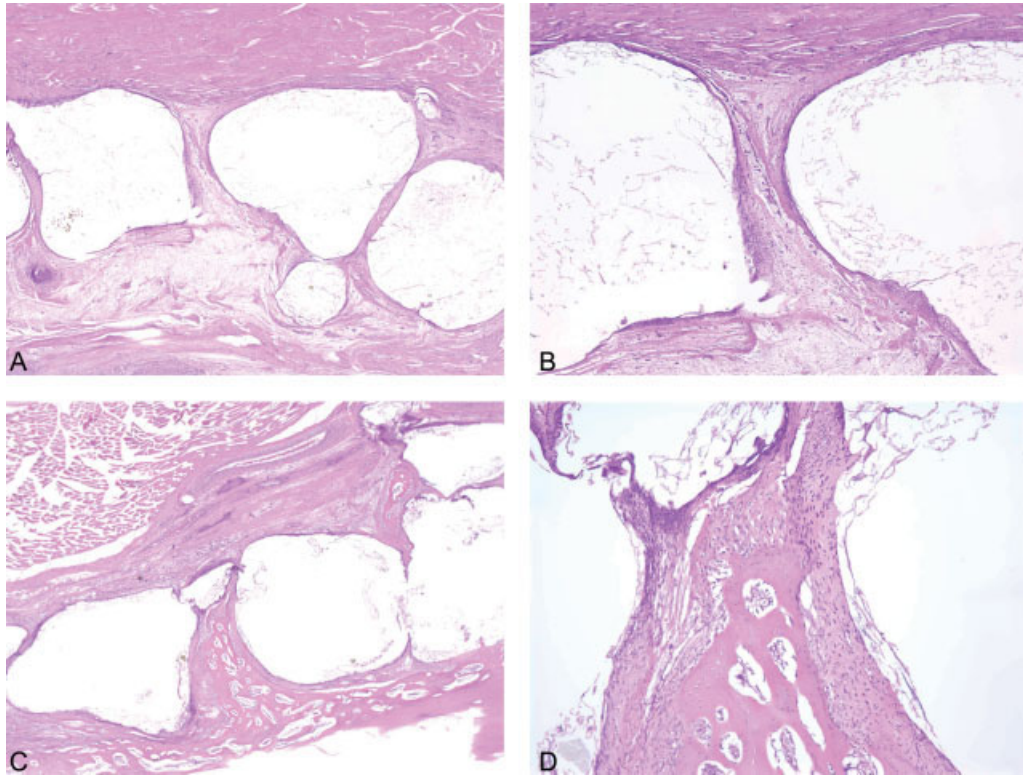


Figure 5. Histological specimens (H&E) of control (A, objective magnification $\times 1.25$; B, objective magnification $\times 10$) and LIPUS (C, objective magnification $\times 1.25$; D, objective magnification $\times 10$) in 4 week rabbit ulna defects. Soft tissue was noted between the β -TCP particles while new bone was found with the addition of ultrasound treatment at 4 weeks. [Color figure can be viewed in the online issue, which is available at www.interscience.wiley.com.]

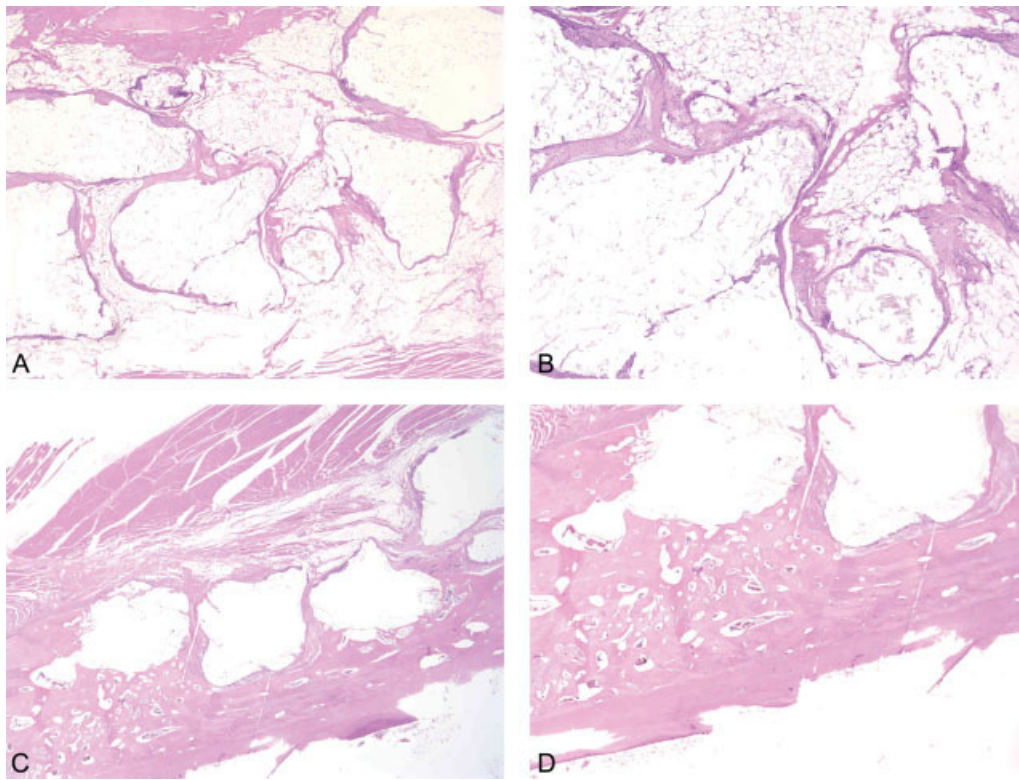


Figure 6. Histological specimens (H&E) of control (A, objective magnification $\times 1.25$; B, objective magnification $\times 10$) and LIPUS (C, objective magnification $\times 1.25$; D, objective magnification $\times 10$) in 12 week rabbit ulna defects. Soft tissue was noted between the β -TCP particles while new bone was found with the addition of ultrasound treatment at 12 weeks. [Color figure can be viewed in the online issue, which is available at www.interscience.wiley.com.]

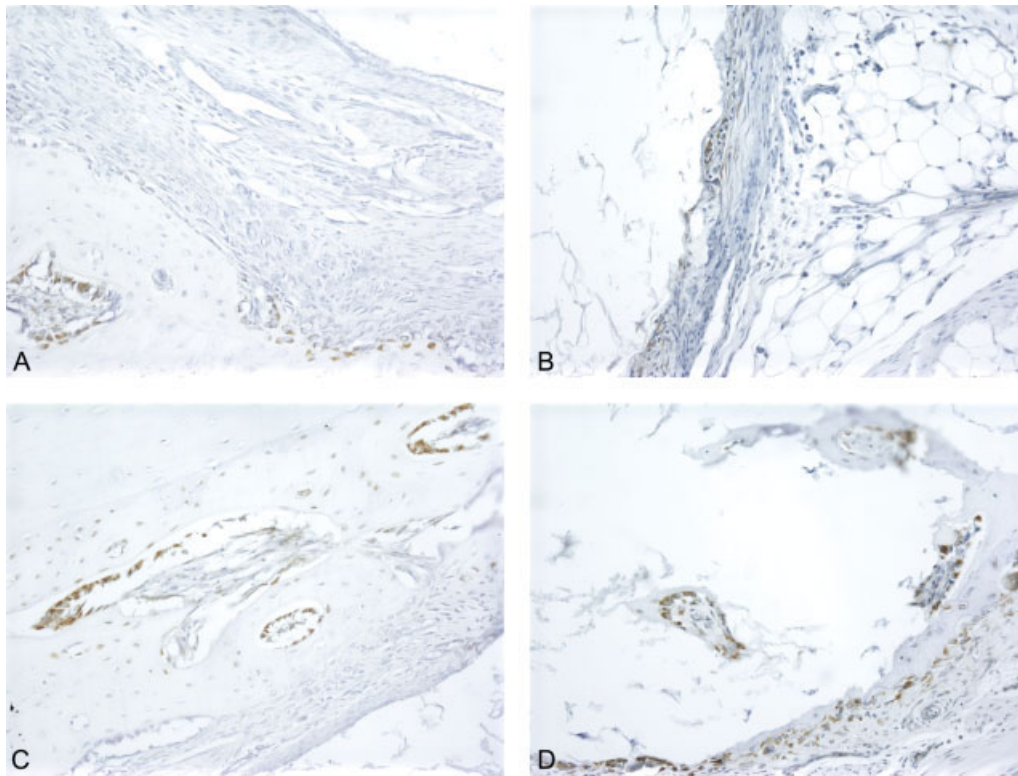


Figure 7. Immunostaining of VEGF-1 in LIPUS treated and control groups. At 4 weeks, the VEGF expression was mainly in the osteoblast cells in the host bone adjacent to the JAX TCP particles (A, C). The expression was elevated in the LIPUS treated animals (C, D) compared with the controls (A, B) at 4 weeks (A, C) and 12 weeks (B, D). The high expression of VEGF is positively correlated with new bone formation (D) (objective magnification $\times 20$). [Color figure can be viewed in the online issue, which is available at www.interscience.wiley.com.]

healing using this β -TCP and that additional factors are required to initiate the healing process. It appears based on the results of our study that LIPUS treatment may provide the osteogenic signal in combination with the β -TCP even without including cell or growth factor based strategies. LIPUS also did not accelerate resorption of the β -TCP in

the rabbit ulna defect model. This supports that LIPUS may be used without altering the resorption profile of this β -TCP and improve bone formation.

A limitation of the current study is the short follow up of 12 weeks. Whilst some evidence of resorption of JAX TCP was noted, 12 weeks was not long enough to allow

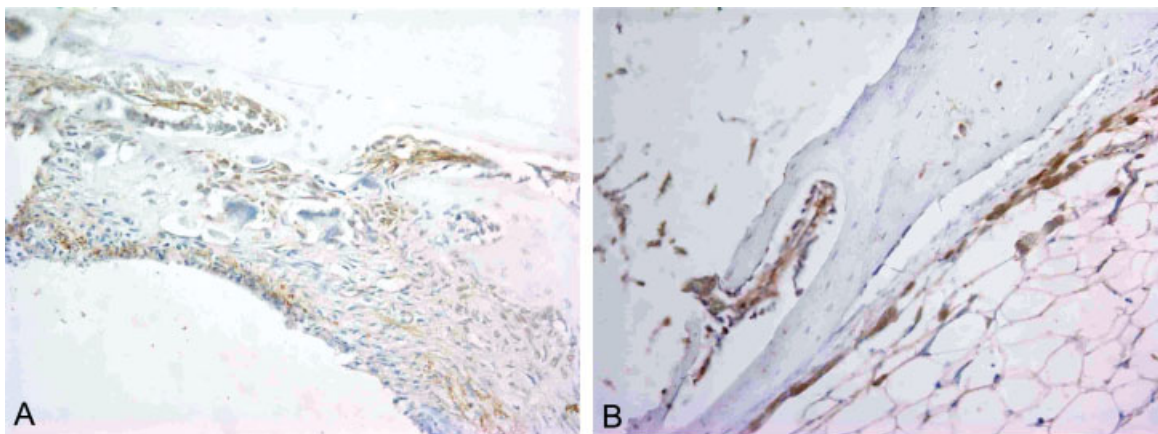


Figure 8. Immunostaining of CBFA1 in LIPUS treated sections. CBFA1 expression was found at actively forming bone fronts at 4 (A) and 12 weeks (B) and the staining was noted in active osteoblasts and mesenchymal cells adjacent to new bone formation (objective magnification $\times 20$). [Color figure can be viewed in the online issue, which is available at www.interscience.wiley.com.]

for sufficient implant resorption in the ulna defect for this material. The JAX TCP material did however provide a scaffold for new bone formation in an osteoconductive fashion as well as avoiding muscle and soft tissue prolapse. The absolute value of the bone mineral density measurements using DEXA must also be treated with care considering the presence of TCP particles in the defect as well as new bone formation. The TCP particles artificially increases the bone mineral density measurements, however considering the same number of particles were placed in each defect the comparison remains valid with the above limitation. We also did not include an empty defect alone and LIPUS treated empty defect groups. However, based on the work of Schortinghuis et al.,¹⁰ LIPUS treatment did not provide any improvement in a critical size mandible defect. The combination of a bone graft substitute scaffold and LIPUS treatment may be a viable treatment option in the case of large, critical size type defects whereby the bone graft substitute provides a suitable scaffold for bone ingrowth and ongrowth along with the positive aspects of ultrasound treatment.

CONCLUSION

The use of low intensity pulsed ultrasound in combination with a β -TCP bone graft substitutes may offer a viable treatment option in the repair of bony defects, thus avoiding the morbidity associated with the use of autograft bone and the limited supply of donor allograft bone.

REFERENCES

1. Heckman JD, Ryaby JP, McCabe J, Frey JJ, Kilcoyne RF. Acceleration of tibial fracture-healing by non-invasive, low-intensity pulsed ultrasound. *J Bone Joint Surg Am* 1994; 76:26–34.
2. Heckman JD, Sarasohn-Kahn J. The economics of treating tibia fractures. The cost of delayed unions. *Bull Hosp Jt Dis* 1997;56:63–72.
3. Hadjiargyrou M, McLeod K, Ryaby JP, Rubin C. Enhancement of fracture healing by low intensity ultrasound. *Clin Orthop* 1998 (355 Suppl):S216–S229.
4. Azuma Y, Ito M, Harada Y, Takagi H, Ohta T, Jingushi S. Low-intensity pulsed ultrasound accelerates rat femoral fracture healing by acting on the various cellular reactions in the fracture callus. *J Bone Miner Res* 2001;16:671–680.
5. Rubin C, Bolander M, Ryaby JP, Hadjiargyrou M. The use of low-intensity ultrasound to accelerate the healing of fractures. *J Bone Joint Surg Am* 2001;83A:259–270.
6. Takikawa S, Matsui N, Kokubu T, Tsunoda M, Fujioka H, Mizuno K, Azuma Y. Low-intensity pulsed ultrasound initiates bone healing in rat nonunion fracture model. *J Ultrasound Med* 2001;20:197–205.
7. Yang K, Park S. Stimulation of fracture healing in a canine ulna full-defect model by low-intensity pulsed ultrasound. *Yonsei Med J (Korea)* 2001;42:503–508.
8. Cook SD, Salkeld SL, Popich-Patron LS, Ryaby JP, Jones DG, Barrack RL. Improved cartilage repair after treatment with low-intensity pulsed ultrasound. *Clin Orthop* 2001(391 Suppl):S231–S243.
9. Nolte P, Klein-Nulend J, Albers G, Marti R, Semeins C, Goei S, Burger E. Low-intensity ultrasound stimulates endochondral ossification in vitro. *J Orthop Res* 2001;19:301–307.
10. Schortinghuis J, Ruben J, Raghoebar G, Stegenga B. Ultrasound to stimulate mandibular bone defect healing: A placebo-controlled single-blind study in rats. *J Oral Maxillofac Surg* 2004;62:194–201.
11. Duarte L. The stimulation of bone growth by ultrasound. *Arch Orthop Trauma Surg* 1983;101:153–159.
12. Zhang ZJ, Huckle J, Francomano CA, Spencer RG. The effects of pulsed low-intensity ultrasound on chondrocyte viability, proliferation, gene expression and matrix production. *Ultrasound Med Biol* 2003;29:1645–1651.
13. Reher P, Doan N, Bradnock B, Meghji S, Harris M. Effect of ultrasound on the production of IL-8, basic FGF and VEGF. *Cytokine* 1999;11:416–423.
14. Korstjens CM, Nolte PA, Burger EH, Albers GH, Semeins CM, Aartman IH, Goei SW, Klein-Nulend J, Marti RK. Stimulation of bone cell differentiation by low-intensity ultrasound—A histomorphometric in vitro study. Low-intensity ultrasound stimulates endochondral ossification in vitro. *J Orthop Res* 2004;22:495–500.
15. Leung KS, Cheung WH, Zhang C, Lee KM, Lo HK. Low intensity pulsed ultrasound stimulates osteogenic activity of human periosteal cells. *Clin Orthop Relat Res* 2004;253–259.
16. Kokubo S, Fujimoto R, Yokota S, Fukushima S, Nozaki K, Takahashi K, Miyata K. Bone regeneration by recombinant human bone morphogenetic protein-2 and a novel biodegradable carrier in a rabbit ulnar defect model. *Biomaterials* 2003;24:1643–1651.
17. Djapic T, Kusec V, Jelic M, Vukicevic S, Pecina M. Compressed homologous cancellous bone and bone morphogenetic protein (BMP)-7 or bone marrow accelerate healing of long-bone critical defects. *Int Orthop* 2003;27:326–330.
18. Yu Y, Walsh WR, Sonnabend DH, Yang JL, Bonar F, Markovic B, Bruce W, Kohan L, Neil M. Cytokines and matrix metalloproteinases mRNA expression in archival human tissues from failed total hip arthroplasty using in situ hybridization and color video image analysis. *Bull Hosp Jt Dis* 1998; 57:23–29.
19. Yu Y, Yang JL, Chapman-Sheath PJ, Walsh WR. TGF-beta. BMPs, and their signal transducing mediators, Smads, in rat fracture healing. *J Biomed Mater Res* 2002;60:392–397.
20. Matsushita N, Terai H, Okada T, Nozaki K, Inoue H, Miyamoto S, Takaoka K. A new bone-inducing biodegradable porous beta-tricalcium phosphate. *J Biomed Mater Res A* 2004; 70:450–458.
21. Stubbs D, Deakin M, Chapman-Sheath P, Bruce W, Debes J, Gillies R, Walsh W. In vivo evaluation of resorbable bone graft substitutes in a rabbit tibial defect model. *Biomaterials* 2004;25:5037–5044.
22. Liljensten E, Adolfsson E, Strid K, Thomsen P. Resorbable and nonresorbable hydroxyapatite granules as bone graft substitutes in rabbit cortical defects. *Clin Implant Dent Relat Res* 2003;5:95–101.
23. Johnson K, Frierson K, Keller T, Cook C, Scheinberg R, Zerwekh J, Meyers L, Sciadini M. Porous ceramics as bone graft substitutes in long bone defects: A biomechanical, histological, and radiographic analysis. *J Orthop Res* 1996;14:351–369.
24. Walsh WR, Chapman-Sheath P, Cain S, Debes J, Bruce W, Svehla M, Gillies R. A resorbable porous ceramic composite bone graft substitute in a rabbit metaphyseal defect model. *J Orthop Res* 2003;21:655–661.
25. Walsh WR, Morberg P, Yu Y, Yang J, Haggard W, Sheath P, Svehla M, Bruce W. Response of a calcium sulfate bone graft substitute in a confined cancellous defect. *Clin Orthop Relat Res* 2003;406:228–236.

26. Dalkyz M, Ozcan A, Yapar M, Gokay N, Yuncu M. Evaluation of the effects of different biomaterials on bone defects. *Implant Dent* 2000;9:226–235.
27. Artzi Z, Weinreb M, Givol N, Rohrer M, Nemcovsky C, Prasad H, Tal H. Biomaterial resorption rate and healing site morphology of inorganic bovine bone and beta-tricalcium phosphate in the canine: A 24-month longitudinal histologic study and morphometric analysis. *Int J Oral Maxillofac Implants* 2004;19:357–368.
28. Bucholz R, Carlton A, Holmes R. Hydroxyapatite and tricalcium phosphate bone graft substitutes. *Orthop Clin North Am* 1987;18:323–334.
29. Gatti A, Zaffe D, Poli G. Behaviour of tricalcium phosphate and hydroxyapatite granules in sheep bone defects. *Biomaterials* 1990;11:513–517.
30. Gosain A, Song L, Riordan P, Amarante M, Nagy P, Wilson C, Toth J, Ricci J. A 1-year study of osteoinduction in hydroxyapatite-derived biomaterials in an adult sheep model. Part I: *Plast Reconstr Surg* 2002;109:619–630.
31. Kamakura S, Sasano Y, Shimizu T, Hatori K, Suzuki O, Kagayama M, Motegi K. Implanted octacalcium phosphate is more resorbable than beta-tricalcium phosphate and hydroxyapatite. *J Biomed Mater Res* 2002;59:29–34.
32. Lange T, Zerwekh J, Peek R, Mooney V, Harrison B. Granular tricalcium phosphate in large cancellous defects. *Ann Clin Lab Sci* 1986;16:467–472.
33. Manjubala I, Sastry T, Kumar R. Bone in-growth induced by biphasic calcium phosphate ceramic in femoral defect of dogs [In Process Citation]. *J Biomater Appl* 2005;19:341–360.
34. Metsger D, Driskell T, Paulsrud J. Tricalcium phosphate ceramic—A resorbable bone implant: Review and current status. *J Am Dent Assoc* 1982;105:1035–1038.
35. Niedhart C, Maus U, Redmann E, Siebert C. In vivo testing of a new in situ setting beta-tricalcium phosphate cement for osseous reconstruction. *J Biomed Mater Res* 2001;55:530–537.
36. Wiltfang J, Merten H, Schlegel K, Schultze-Mosgau S, Kloss F, Rupprecht S, Kessler P. Degradation characteristics of alpha and beta tri-calcium-phosphate (TCP) in minipigs. *J Biomed Mater Res* 2002;63:115–121.
37. Clarke SA, Hoskins NL, Jordan GR, Marsh DR. Healing of an ulnar defect using a proprietary TCP bone graft substitute. JAX, in association with autologous osteogenic cells and growth factors. *Bone* 2007;40:939–947.